

Canine Dental Chart

Date: 5/15/2014

Owner's Name: Fritz & Carolyn Von Valtier

Client ID: 25182

Sex: Spayed Female

Skull type: Mesocephalic

Medical or Anesthesia Concerns: Geriatric, dislikes handling of mouth & ears.

Pre-medication: Simplicef 100mg PO, Hydromorphone 0.8 mL IM (1.6 mg).

IV fluids: 20 ga. IV catheter placed in L cephalic v., LRS run at 190 mL/hr during procedure, 38 mL/hr after procedure.

Anesthesia: Rompun 0.5 mL IV (10 mg), Propofol 1.5 mL IV (15 mg), intubated & maintained on O2 & Isoflorane ~1-1.5%.

Pain medication: L maxillary regional nn block of 0.4 mL bupivacaine/lidocaine mix, as well as splash application of bupivacaine/lidocaine mix on all sites of gingival hyperplasia trimming & cautery.

Antibiotics Dispensed: Simplicef 100 mg PO SID x 14 days - started this morning before anesthesia.

Clindoral gel (clindamycin) applied to periodontal pockets.

Endotracheal Tube Size: 8.0 mm

Recommended . . . chew toys

X-rays Taken? No

Teeth Extracted and Reasons: None

Additional Procedures: Trimmed & cauterized hyperplastic gingiva - 104, 105, 204, 205, 206, 207, 304, 404.

Recheck: if problems arise

I: 3/3 C: 1/1 PM: 4/4 M: 2/3

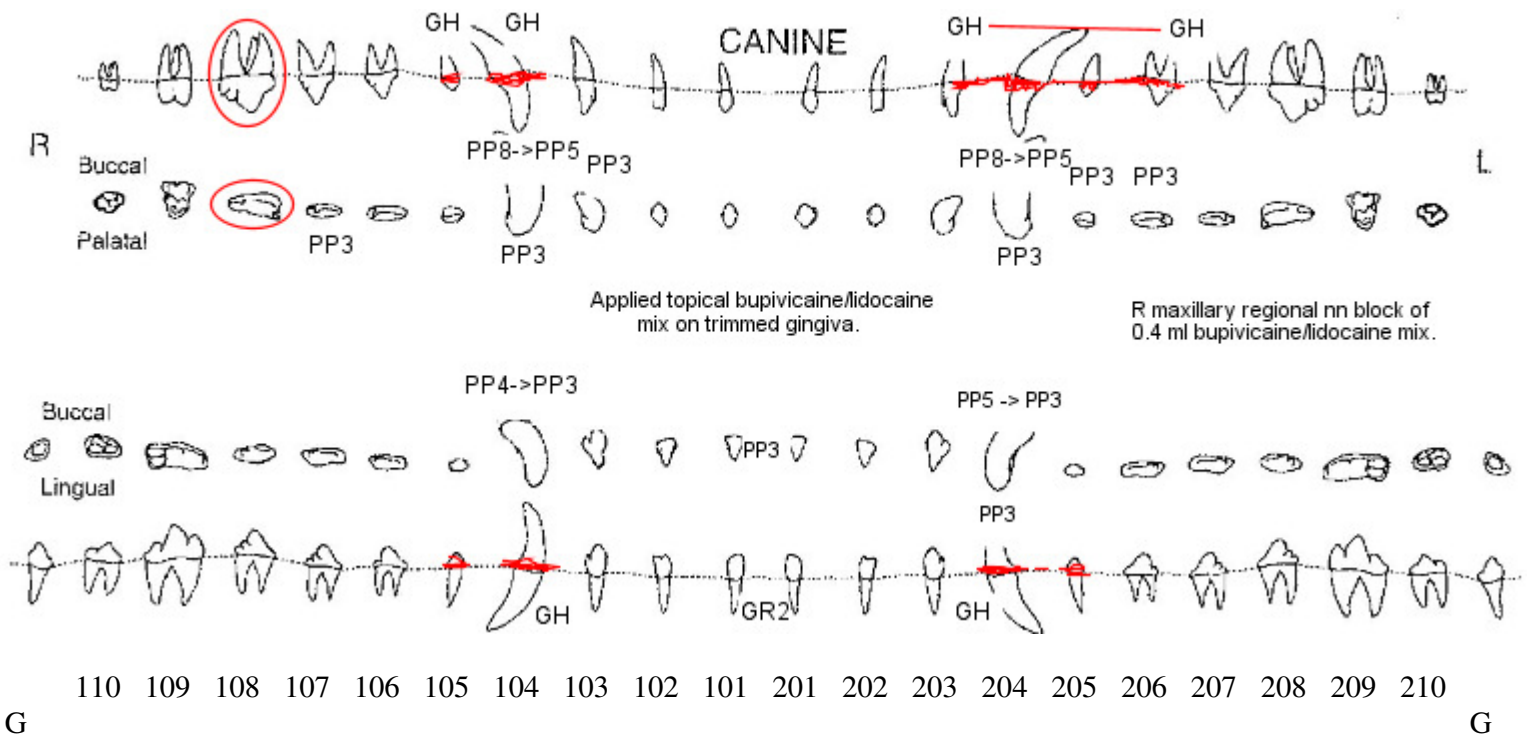
Doctor: Eleanor J. Jones, DVM

Technician: Sara Riley LVT

Weight: 38 pounds

BCS: 5/9

Stage of Periodontal Disease: II/IV



Applied topical bupivacaine/lidocaine mix on trimmed gingiva.

R maxillary regional nn block of 0.4 ml bupivacaine/lidocaine mix.

411 410 409 408 407 406 405 404 403 402 401 301 302 303 304 305 306 307 308 309 310 311

Abbreviation Key:

AB- Abrasion (worn teeth)

AT - Attrition (teeth rubbing causing wearing)

CWD - Crowding

ED - Enamel defect

EP - Epulis

F1,2,3 - Furcation stages

GH - Gingival Hyperplasia

GR - Gingival Recession

NV - Non-vital

M1+ to M3+ - Mobility (1+ is slightly loose, 3+ is very loose)

UCCF- Uncomplicated crown fracture (pulp not involved)

UCRF - uncomplicated root fracture (involves crown/root - not pulp)

RF - root fracture (crown is intact , but root is fractured)

O - Missing (circled)

PE - Pulp exposure

PP - Periodontal pocket

RL - Resorptive Lesion

ROT - Rotated Tooth

RR - Retained root

S - Stained tooth

SUP - Supernumary tooth

X- Extraction

Gingivitis Box Scores

O = normal gingival tissue

I = Thin, red gingival line, no bleeding

II = moderate swelling, "rolled" gingiva, some bleeding

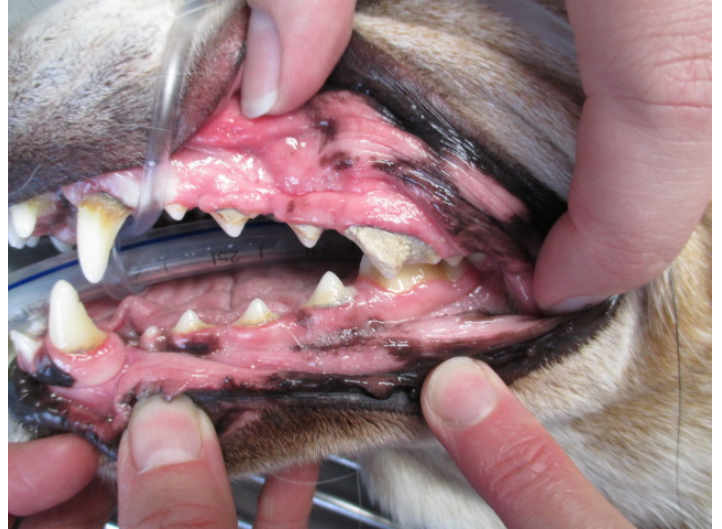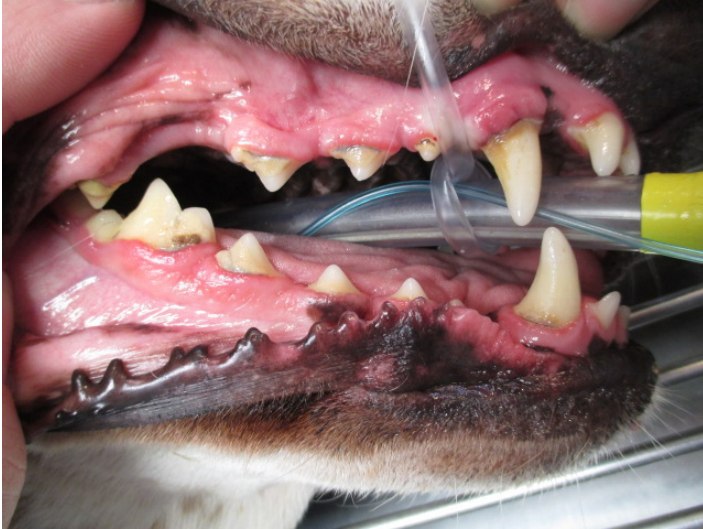III = marked swelling, bleeds easily

CCF - complicated crown fracture (involves crown/pulp)

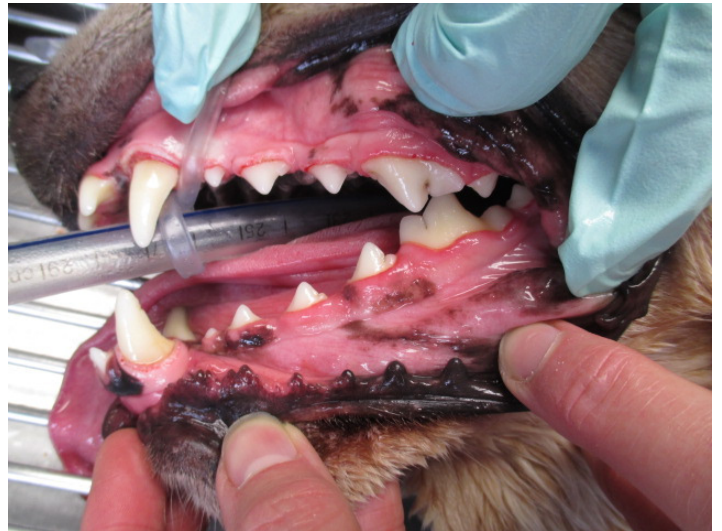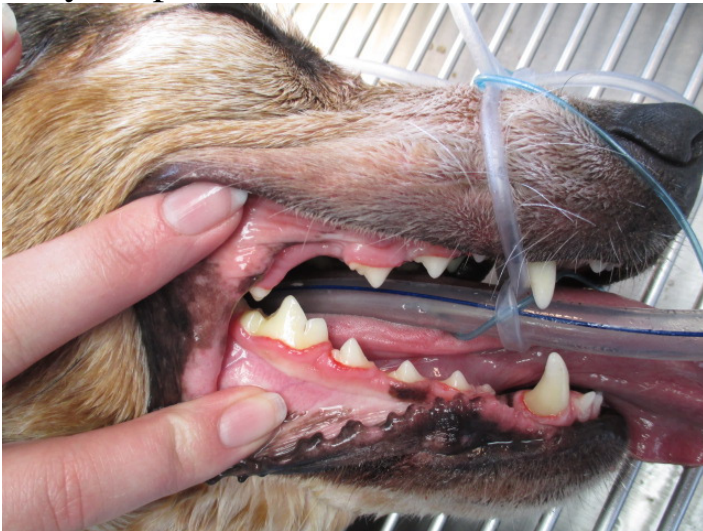Patient Name: Sandy Von Valtier

Date: 5/15/2014

What your pet's mouth looked like before it was cleaned:



How your pet's mouth looks now:



ADDENDUM on 5/15/2014 at 20:57:54 from **Eleanor J. Jones, DVM**

Lots of hair trapped in midline of tongue with foul odor. Hair removed & flushed.

5/15/2014 Canine Dental Chart - Periodontal dz - IV fluids, trimmed hyperplasia, cautery, Clindoral, S

***ADDENDUM 5/15/2014

Jones, DVM, Eleanor J. - Final - 5/15/2014